

# A Novel Specialized Suture and Inserting Device for the Resuspension of Ptotic Facial Tissues: Early Results

EMIL BISACCIA, MD,\* RAZAN KADRY, MD,† LILIANA SAAP, MD,† ARLENE ROGACHEFSKY, MD,† AND DWIGHT SCARBOROUGH, MD†

---

**BACKGROUND** In the past decade, the popularity of minimally invasive procedures for facial rejuvenation has increased.

**OBJECTIVE** To describe a new specialized suture, and its associated technique, used to elevate sagging tissues of the face and neck.

**METHODS** A detailed description of the technique and the results obtained in 20 patients in whom we have used this novel approach. Attention was given to appropriate patient selection. The primary focus was on the correction of the jowl, jawline, and neck subunits. It involves the percutaneous introduction of a novel 3-0 polypropylene suture that has 10 absorbable hollow cones along its axis that are equally interspersed with knots. Once the absorbable cones are resorbed into the surrounding tissues, the non-absorbable suture component can be removed without compromising the aesthetic outcome.

**RESULTS** All patients demonstrated improvement in these areas, with minimal complications. One patient required resuspension using the open technique. (Excessive ptotic tissue was later excised for an optimal cosmetic result.)

**CONCLUSION** The suture and technique described in this article provide a major contribution to the correction of ptosis of facial tissues. When done in conjunction with other procedures, such as neck and jowl microliposuction, this technique has proven to be a useful addition to facial rejuvenation.

*The authors have indicated no significant interest with commercial supporters.*

---

Surgical management of the aging face has incorporated a wide range of new techniques over the past few years. Traditional face-lifting procedures have employed historically more aggressive methods.<sup>1</sup> Because of the recent shift in the population's interest in less invasive procedures, the newer surgical techniques have approached the reversal of senescent changes of the face in a different fashion. Ultimately, patients are seeking out procedures that have little downtime coupled with longer-lasting results and a favorable side-effect profile. For this reason, dermasurgeons are continually adapting newer and safer approaches to reversing ptotic changes of the maturing face.

A youthful and appealing contour of the neck is usually defined by a cervical mental angle of 90° and

not exceeding 120°. Senescent changes of the mature neck include accumulation of fat, laxity of muscular support, and the cumulative effects of photodamage and gravity.

The aforementioned anatomical changes contribute to the loss of definition of the cervical mental angle, submental fullness, sagging of the jowls, and platysmal band formation. Comprehensive facial rejuvenation should address treatment of the individual subunits as sums of a whole for the most successful outcome.<sup>2,3</sup>

Although this technique is applicable to any area of the aging face, here we present the use of this simplified method to restore a proper cervical mental angle with concomitant reduction in the platysmal


---

\*Clinical Dermatology, Columbia University College of Physicians and Surgeons, New York, New York; †Department of Dermatology, Ohio State University, Columbus, Ohio

bands. This technique restores a more youthful appearance to the anterior face and neck in a minimally invasive fashion. This procedure may be done in conjunction with neck and jowl liposuction for optimal results.

### Materials and Methods

The following materials are required for this procedure: a Silhouette suture made of a 3-0 polypropylene suture substrate and attached to an 8 straight needle (K.M.I. Kolster Methods Inc., Corona, CA). The suture's axis has 10 absorbable cones equally spaced by knots 8 mm apart. The flexible hollow cones are composed of an absorbable copolymer of glycolic and lactic acid. Included with the Silhouette suture kit is an optional blunt needle insertion device, or catheter, that slips over the 8 straight needle. This delivery device aids in introduction of the suture in the appropriate plane (Figure 1). One or more sutures may be deployed in the same plane for an optimal outcome. A #11 blade with its handle, Metzenbaum scissors, a 4-mm spatula liposuction cannula, and a standard tray for neck and jowl liposuction are required as well. Tumescence anesthetic solution of the Modified Kleins type is also used in this procedure. Monitored anesthetic care (MAC) (conscious sedation) is optional.



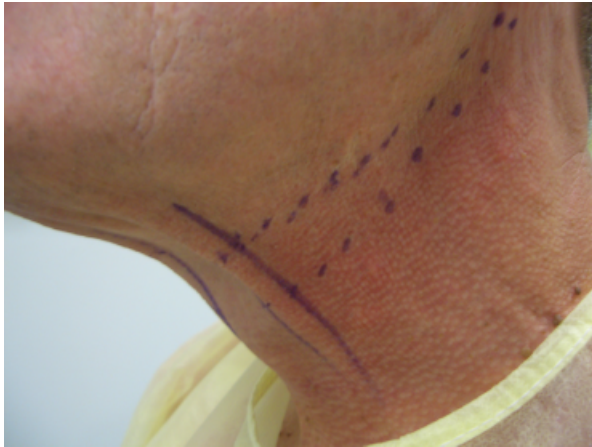**Figure 1.** Silhouette suture and insertion device kit.

Appropriate patient selection is necessary for the best results. Twenty patients signed an informed consent for this procedure. Patients with jawline laxity are seen in consultation, and the age-derived contour changes are highlighted. This minimally invasive procedure is ideally suited for a relatively young patient with laxity in the jawline and neck and early platysmal banding.<sup>4</sup> This technique is especially suited to patients who present clinically with early blunting of the mandibular angle with or without laxity of skin in the anterior neck that is a direct anatomic result of a division in the patient's platysmal muscle along the midline. Skin elasticity should be of moderate turgor, which can be assessed using the snap test. If the patient has a negative snap test (the skin does not return back to its original position after the application of opposing tension), the patient is not a good candidate for this minimal incision procedure. Therefore, patients with extensive tissue laxity are not good candidates and may require a more conventional method of face-lifting surgery.

Once patients are appropriately selected, the perioperative management includes a detailed and frank discussion of the realistic expectations of such a procedure. Most of our patients undergoing this procedure receive monitored intravenous conscious sedation in an ambulatory surgical suite and perioperative intravenous cephalosporin, although the procedure was conducted in two of our patients solely with local tumescence anesthesia, with the use of preoperative antibiotics (cephalosporin).

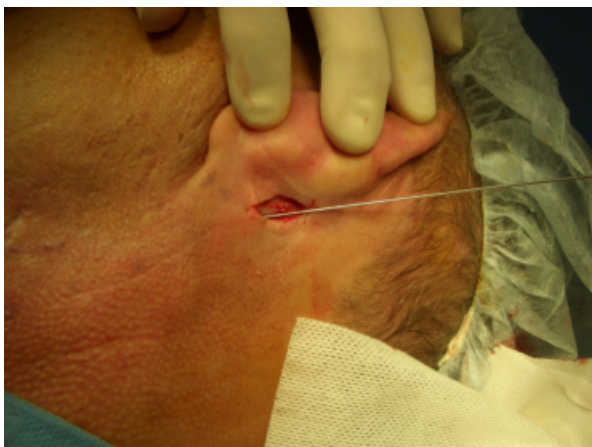After the patient is marked in an upright position, he or she is prepped and draped for sterility (Figure 2).

After light sedation is achieved, local anesthesia is employed using 1% lidocaine with 1:100,000 epinephrine. This is injected along a premarked 1.5-cm postauricular incision site. An incision is made then to the level of the supra-superficial muscular aponeurotic system (SMAS) layer in the posterior auricular sulcus (Figure 3).



**Figure 2.** Markings on the patient in an upright position.

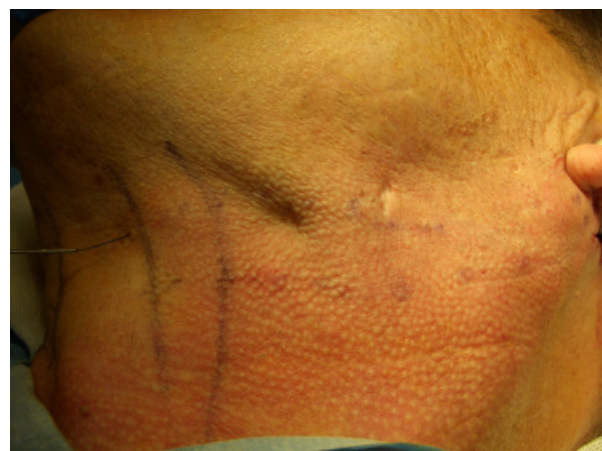A #11 blade is used to make a nick incision in this vicinity through which the tumescent anesthetic solution is introduced. The tumescent solution consists of 0.1% lidocaine with 1:1,000,000 epinephrine in a lactated Ringer's solution. A submental nick incision is only used if neck and jowl liposuction are going to be concomitantly performed using the resuspension technique. Hydrodissection is performed in the subcutaneous plane above the SMAS, with the assistance of a showerhead infusion cannula attached to a 60-mL syringe. Metzenbaum scissors or a 4-mm spatula liposuction cannula is used for minimal and blunt undermining at the supra-SMAS level. Blunt dissection is further performed by extending anteri-



**Figure 3.** Incision in the posterior auricular sulcus through which the Silhouette suture is introduced.

orly from the posterior auricular area to the width of two finger breadths anteriorly along the jawline toward the submental crease, establishing a subcutaneous plane above the SMAS. Then, the 8 straight needle end of the Silhouette suture is introduced through the posterior auricular incision behind the gonion into the supra-SMAS plane and advanced toward the menton. At this point, the straight needle punctures the overlying skin, and the distalmost point of the suture is pulled through, exiting the skin in the vicinity of the submentum. Once all of the stabilizers are situated completely in the subcutaneous plane, the suture is then unsheathed from the proximal end (Figure 3). The entire Silhouette suture unit is then pulled in a superolateral direction through the posterior auricular incision until the desired smoothing of the platysmal bands and restoration of the proper cervical mental angle is achieved (Figure 4).

It is important to note that the proximal end of the Silhouette suture has a curved needle end that is used to puncture a suture mesh. At this time, the curved needle end of the suture is passed through the fascia, passed again through the fascia in the opposite direction, and then tied to itself. This, in turn, is tied down and fastened to the underlying subauricular



**Figure 4.** The Silhouette suture is pulled taut in a superolateral direction manually to note the proper placement of thread. Note: The adjacent scar is unrelated to the procedure.

fascia. Each individual Silhouette suture that is used is also fastened in a similar fashion to secure the redefinition of the cervical mental angle (Figure 5).

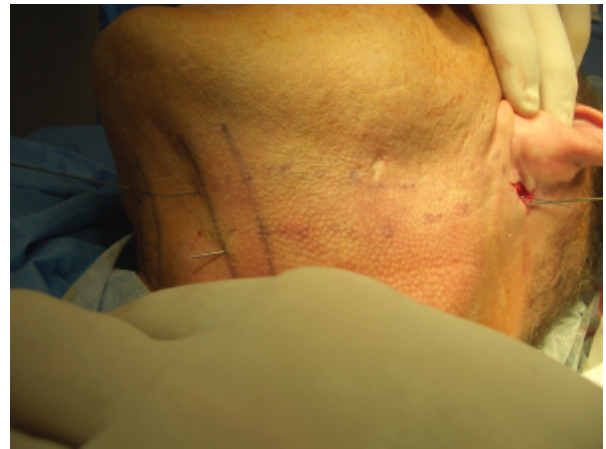Finally, the 8 needle is trimmed off in the submental area level with the cutis. More than one Silhouette suture can be used, but they should ideally be deployed at least 1 cm apart (Figure 6).

The overlying incision is then sutured with 5-0 running prolene suture that is removed 7 days postoperatively<sup>5</sup> (Figure 7).

### Results

We have used this resuspension technique in 20 patients since its approval by the Food and Drug Administration in May 2007 for jawline resuspension and platysmal band correction. This procedure can also be an adjunct to neck and jowl liposuction, supporting the tissue after fat removal (Figure 8A and B). Seventeen patients have had excellent results, and two have had good outcomes. One patient required a second procedure to further define the cervical mental angle (Figure 8A–J).

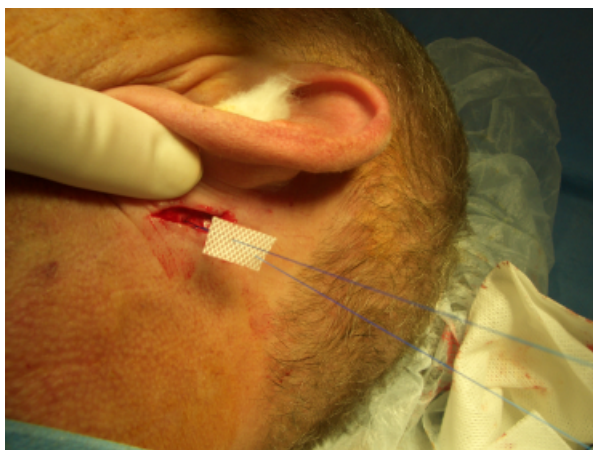Besides having the expected localized ecchymoses, edema, and tenderness, one patient had a sensory



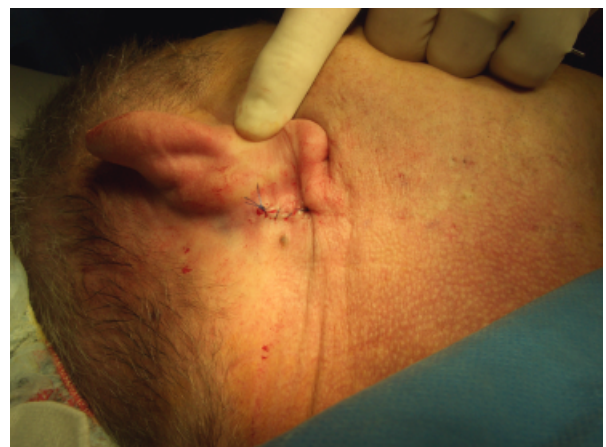**Figure 6.** More than one Silhouette suture may be deployed at least 1 cm apart from one another.

dysesthesia, which resolved spontaneously within 2 weeks after the procedure.

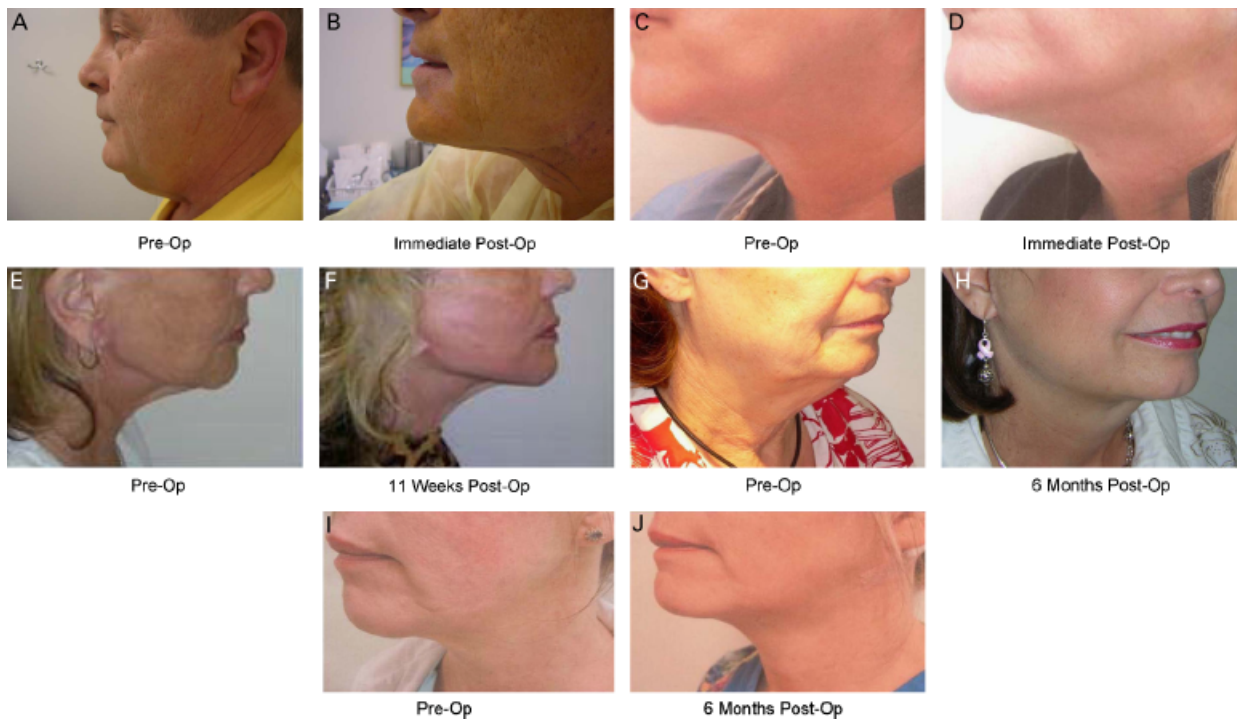No infection or knot abscesses have been observed. We have followed our patients for 6 months postoperatively and have found that they have retained sharp jawline definition and cervical mental angle positioning throughout this time period. We plan to follow these patients to observe the long-term efficacy of this modality.



**Figure 5.** The proximal end of the Silhouette suture is inserted through the mesh with the aid of the curved needle end. The sutures are then fastened to the underlying fascia.



**Figure 7.** The overlying incision is sutured with 5-0 prolene.



**Figure 8.** Pre- and postoperative results of different patients at various intervals. (A) Preoperative. (B) Immediately postoperative. (Patient underwent liposuction of neck along with the Silhouette suture). (C) Preoperative. (D) Immediately postoperative. (E) Preoperative. (F) 11 weeks postoperative. (G) Preoperative. (H) 6 months postoperative. (Patient underwent liposuction of neck along with the Silhouette suture.) (I) Preoperative. (J) 6 months postoperative.

## Discussion

As one matures, redundancy of the neck skin and jowl formation becomes more noticeable, as do rhytides and furrows. The dermatologist must also take into consideration the vectors of aging, which parallel the forces of gravity. In the lower face, the cheek and platysmal muscle are gradually displaced inferomedially. This is first noticed toward the end of the third decade. These changes may be observed at an earlier age with advanced extrinsic aging factors such as photodamage, obesity, and smoking.<sup>2,3</sup> Because there is an ever-increasing popular interest in beauty, there is a paralleled exponential increase in the variety of correction modalities used today to correct these senescent changes.

The youthful jawline at the inferior margin of the lower face is sharp and uninterrupted, forming the desirable V shape of the face. With the increasing laxity and sagging of the lower cheek skin, the angle

of the jaw becomes more obtuse, forming the U configuration of the aging face. The goal of the lifting procedure is to direct tension in the opposite direction to the aging vector. Along the jawline, there is further emphasis on restoring the sharpness of the cervical mental angle.

Suture lifting is not comparable with and should not be presented as an alternative to a face-lift.<sup>6</sup> Rather, it is a temporizing approach to the aging face. There is an ongoing evolution in the uses of various threads for lifting sagging tissues to delay the need for a conventional face-lift.<sup>7</sup>

Eremia and Willoughby recently published their results on 20 patients using a novel absorbable suspension suture termed the Monograms suture along with its inserting device. The patients were followed for 12 months postoperatively. In patients with a pure suspension lift (no skin excision), 80% to 100%

of the correction appeared lost at the 1-year follow-up visit, but in patients who used this absorbable suspension suture in conjunction with relatively conservative skin excision, the 1-year follow-up results remained excellent.<sup>8</sup>

Although historically enjoying great popularity, barbed sutures have not been used as frequently.<sup>9</sup> There have been reports of their migration distant from their points of insertion and their association with painful dysesthesias.<sup>10,11</sup>

Because no suspension suture has been used without some pitfalls, there remains an ongoing interest in developing novel suspension sutures that achieve relatively long-term results in as minimally as disruptive a nature as possible.

Because of the presence of “cuts” in the axis of the barbed suture, it is intrinsically weakened, which creates a venue for a greater risk of rupture and subsequent migration of broken suture material.<sup>12</sup>

Because the Silhouette suture has no cuts in its main structure, its intrinsic strength is preserved. Also, the absorbable cones and equally interspersed knots allow for the gradual infiltration of new collagen. This secondary anchoring system is completed at 6 to 9 months, during which time the body absorbs the copolymer of glycolic and lactic acid that the hollowed cones are composed of in a circumferential fashion along the longitudinal axis of the suture.

Subsequently, the polypropylene suture may or may not be extracted afterward through the posterior auricular incision without compromising the resultant long-term tissue resuspension. Therefore, this minimally invasive conservative approach to tissue resuspension has resulted in excellent results thus far, without permanent adverse sequelae. Furthermore, we have used the Silhouette suture without concomitant skin excision and achieved good results.

In conclusion, this novel suspension suture and its inserting device resulted in excellent correction of ptotic facial and neck tissues in our cohort of 20 patients. Long-term studies are encouraged to establish its protracted efficacy in minimally invasive tissue resuspension.

## References

1. Webster RC. Conservative face lift surgery. *Arch Laryngol* 1976;102:657–82.
2. Bisaccia E, Scarborough DA. Facial analysis. In: Cooke DB, Noujaim SR, Shelnis LA, editors. *Columbia Manual of Dermatologic Surgery*. New York: McGraw-Hill; 2002. p. 61–83.
3. Beeson WH. Facial analysis. In: Beeson WH, McCollough EG, editors. *Aesthetic Surgery of the Aging Face*. St. Louis: Mosby; 1986. p. 1–9.
4. Bisaccia E, Khan AJ, Herron JB, Scarborough DA. Resuspension of mild to moderate jawline laxity using a minimally invasive technique. *Dermatol Surg* 2003;29:810–6.
5. Scarborough, et al. Microliposuction and neck rejuvenation utilizing a minimally invasive procedure. Presented at the American Society for Dermatologic Surgery, Chicago, IL 2007.
6. Hochman M. Midface barbed suture lift. *Facial Plast Surg Clin North Am* 2007;15:201–7.
7. Lee S, Isse N. Barbed polypropylene sutures for midface elevation: early results. *Arch Facial Plast Surg* 2005;7:55–61.
8. Eremia S, Willoughby MA. Novel face-lift suspension suture and inserting instrument: use of large anchors knotted into the suture with attached needle and inserting device allowing for single entry point placement of suspension suture. Preliminary report of 20 cases with 6- to 12-month follow-up. *Dermatol Surg* 2006;32:335–45.
9. Sulamanidze MA, Fournier PF, Paikidze TG, Sulamanidze GM. Removal of facial soft tissue ptosis with special threads. *Dermatol Surg* 2002;28:367–71.
10. Silva-Siwady JG, Diaz-Garza C, Ocampo-Candiani J. A case of Aptos thread migration and partial expulsion. *Dermatol Surg* 2005;31:356–8.
11. Lee CJ, Park JH, You SH, et al. Dysesthesia and fasciculation: unusual complications following face-lift with cog threads. *Dermatol Surg* 2007;33:253–5.
12. Rashid RM, Sartori M, White LE, et al. Breaking strength of barbed polypropylene sutures: rater-blinded, controlled comparison with non-barbed sutures of various calibers. *Arch Dermatol* 2007;143:869–72.

---

Address correspondence and reprint requests to: Razan Kadry, MD, Affiliated Dermatologists and Dermatologic Surgeons, P.A. 182 South Street, Suite 1, Morristown, NJ 07960, or e-mail: razankadry@yahoo.com